

# Tau-protein expression in human blood lymphocytes: a promising marker and suitable sample for life-time diagnosis of Alzheimer's disease

Igor M. Kvetnoy,<sup>1,2</sup> Jose Hernandez-Yago,<sup>1</sup> Tatiana V. Kvetnaia,<sup>2</sup> Vladimir Kh. Khavinson,<sup>3</sup> Vladimir V. Malinin,<sup>3</sup> Alexander A. Yarilin,<sup>4</sup> Nina I. Sharova,<sup>4</sup> Jose R. Blesa,<sup>1</sup> Vladimir N. Anisimov,<sup>3</sup> Lilia V. Lenskaia,<sup>5</sup> Sofia F. Sluchevskaia,<sup>5</sup> Svetlana I. Chekalina,<sup>2</sup> Oleg Yu. Tokarev<sup>2</sup> & Vadim V. Yuzhakov<sup>2</sup>

1. Instituto de Investigaciones Citologicas, Valencia 46010, Spain.
2. Medical Radiological Research Center, Obninsk 249020, Russia.
3. Institute of Bioregulation and Gerontology, St. Petersburg 197110, Russia.
4. Institute of Immunology, Moscow 115522, Russia.
5. Municipal Geriatric Center, St. Petersburg 197110, Russia.

*Correspondence to:* Prof. Igor M. Kvetnoy, M.D., Ph.D.  
Instituto de Investigaciones Citologicas  
Amadeo de Saboya, 4  
46010 Valencia, Spain  
TEL: +34-96-339 12 50  
FAX: +34-96-360 14 53  
E-MAIL: kvetnoy@ochoa.fib.es

*Submitted:* March 23, 2000  
*Accepted:* May 27, 2000

*Key words:* **Alzheimer's disease; tau-protein; immunocytochemistry; peripheral blood lymphocytes.**

*Neuroendocrinology Letters 2000; 21:313-318* Copyright © Neuroendocrinology Letters 2000

## Abstract

**OBJECTIVES:** Taking into account the hypothesis that Alzheimer's disease (AD) might be a systemic disease that affects several tissues in the body, the aim of this study was to try to detect the expression of tau-protein in human peripheral blood lymphocytes (PBL) in patients with AD. **MATERIAL AND METHODS:** Blood samples were obtained from patients with AD (n=16, age 67-98) and from volunteers without psychoneurological pathology (n=10, age 65-78). PBL were isolated on Ficoll-Paque gradient centrifugation. For cell fixation and permeabilization we used a fixative solution (4% formaldehyde and 0.1% glutaraldehyde) and 0.03% Triton X-100. Immunocytochemical detection of tau-protein was carried out by biotin-streptavidin complex method with tau monoclonal antibody (1:100, clone TAU-2, ICN) and universal immunostaining kit IMMU-MARK (ICN). **RESULTS:** The expression of tau-protein was shown in PBL in absolute majority of AD patients studied. Only in two healthy volunteers a single lymphocyte from many cells (i.e. a smear) demonstrated a very weak-positive immunostaining to tau-protein. **CONCLUSION:** This first demonstration of clear difference in localization of tau-protein in blood lymphocytes between healthy and sick people testifies to the fact that tau-protein could be considered as a promising marker and blood lymphocytes as a suitable sample for life-time diagnosis of AD.

## Introduction

Alzheimer's disease (AD) is one of the most important neurodegenerative disorders and may be one of the most frequent causes of death in XXI century. AD is characterized by a progressive loss of memory, resulting in dementia and death [1]. AD affects over 20 million people worldwide and this incidence is expected to double over the next 30 years [2].

While the patient is alive, it is not easy for a physician to tell the difference between various forms of dementia. The diagnosis of a specific form of dementia as AD manifestation is confirmed finally by a pathologist only at autopsy using specific histochemical and immunohistochemical methods. This circumstance dictates the necessity to develop life-time markers for diagnosis and prognosis of AD as well as of other neurodegenerative diseases.

The study of extra-brain tissues and cells which are available for biopsy could be very promising for this purpose. There are several reports to identify the cellular and molecular abnormalities as well as the characteristic neuropathological lesions of AD in autopsied extra-brain tissues (liver, pancreas, ovary, testis, thyroid and others) and non-autopsied cells (skin fibroblasts, blood lymphocytes and platelets) [3–5]. The study of peripheral cells is based on the supposition that AD might be a systemic disease that affects several tissues in the body [6]. The observations indicated the formation of curly fibers or tangles not only in the brain but in many visceral organs [7] as well as the indication of  $\beta$ -amyloid precursor protein ( $\beta$ -APP) in skin fibroblasts, platelets and lymphocytes [8, 9] may be considered as an additional confirmation of this hypothesis.

Most publications on the use of peripheral cells for diagnosis of AD are devoted to study skin fibroblasts. From our point of view the peripheral blood lymphocytes (PBL) could be considered as more suitable samples for the research in this field of study for the following reasons: it is easy to receive the fractions of any type of lymphocytes from human blood; it is known that lymphocytes produce many biologically active substances, including cytokines,  $\beta$ -APP, biogenic amines and regulatory peptides, which could be involved in the pathogenesis of AD and other neurodegenerative diseases; immunocytochemical methods for evaluation of these substances in lymphocytes are well developed.

There are two key molecules which are involved in the pathogenesis of AD:  $\beta$ -amyloid and tau-protein [10, 11]. In spite of many attempts, there are no well-established facts showing that one of the key mol-

ecules for AD  $\beta$ -APP may be produced by lymphocytes of AD patients [12]. Thus, it is necessary to try to detect tau-protein in human blood lymphocytes.

Tau is a microtubule-associated phosphoprotein that is involved in microtubule assembly and stabilization [13]. In adult human brain neurons, six isoforms of tau are expressed, which are produced by alternative splicing of mRNA from a single gene located on the long arm of chromosome 17 [14]. In AD, tau-protein becomes abnormally phosphorylated, aggregates into parietal helical filaments and loses its ability to maintain the microtubule tracks [15]. In some recent studies the expression of tau-protein has also been shown in cultured skin fibroblasts from AD patients [16,17].

Moreover, the subsequent CERAD (consortium to establish a registry for Alzheimer's disease) criteria referred more specifically to neuritic plaques, with the recently added emphasis on tau-protein deposits such as neurofibrillary tangles (Consensus criteria, National Institute of Aging and Reagan Institute, USA) [18].

Taking this into account as well as the circumstances mentioned above, we tried to detect the second crucial molecule for AD pathology—tau-protein—in human PBL, and if so, to discuss the perspectives to use these cells as a sample for life-time diagnosis of AD and other neurodegenerative pathology.

## Materials and Methods

**Clinical data.** Blood samples were obtained from patients with mild to moderate probable AD according to the National Institute of Neurological and Communicative Disorders Association (NINCDS-ADRDA) criteria ( $n = 16$ , age 67–98 years, males and females, Mini Mental State— $MMS \pm SD = 22 \pm 5$ , MMS range 17–26, duration of the disease: mean  $\pm SD = 3.4 \pm 1.6$  years, range 2–7 years. The Structured Interview for the Diagnosis of Dementia score was  $36 \pm 12$  (max. 54). Clinical Dementia Rating (CDR) was the following: five patients were CDR stage 1 (mild dementia) and 11 patients were CDR stage 2 (moderate dementia). Blood samples from 10 volunteers without psychoneurological pathology (age 65–78, 4 men and 6 women) were used for the control study. Informed consent was given by each patient before each investigation.

**Preparation of peripheral blood lymphocytes (PBL).** Blood samples from AD patients and healthy volunteers were defibrinated and diluted with Hank's balanced salt solution (1:1) and then layered

over a Ficoll-Paque (Amersham, UK). Lymphocytes were isolated on Ficoll-Paque at room temperature ( $\delta 1.077$ , 500 g, 40 min). Phagocytes were removed with carbonyl iron after gradient centrifugation. Purified lymphocytes were washed three times at room temperature using 0.1M phosphate-buffered saline (PBS, pH 7.2). About 95% of cells present in the PBL fractions were mononuclear cells by morphology on the smear staining by May-Grunwald method.

**Cell fixation and permeabilization.** PBL were washed by PBS and resuspended in 10 ml fixative solution (4% formaldehyde and 0.1% glutaraldehyde) during 10 min. After fixation the cell suspension was immediately diluted with PBS, centrifuged, and washed twice with PBS. After this step PBL were permeabilized with 0.03% Triton X-100 (Sigma, USA). Triton X-100 treatment was done during 20 min at 4° temperature, then cell suspension was washed twice with PBS. After this step, the smears from PBL suspension were prepared on microscopic glasses.

**Immunocytochemical staining.** Cell smears were washed with 0.1M PBS (pH 7.2) and incubated with primary tau monoclonal antibody (1:100, clone TAU-2, ICN, USA,) at room temperature for 2h, followed by three washes with PBS. This antibody reacts exclusively with the chemically heterogenous Tau-protein in both the phosphorylated and non-phosphorylated form. Fast DAB with Metal Enhancer tablets (Sigma, USA) were used to prepare substrate solution, and all the next steps were carried out using universal immunostaining kit IMMU-MARK (ICN, USA) according to standard commercial protocol.

Sections of post-mortem cerebral cortex of five AD patients were employed as positive controls and cell smears from both groups, studied without incubation in primary antibody, were used as negative controls.

Smears were analyzed and photodocumented with a Zeiss Axiophot-2 microscope.

## Results

The immunocytochemical study carried out to identify intracellular tau-protein reveals that the vast majority of PBL in AD patients exhibited tau-positive staining (Fig 1a): strong positive reaction was apparent in 15 of 16 cases. In one case of the AD patients, we registered a weak tau-protein expression in PBL. Conversely, in 8 of 10 volunteers, PBL had no immunoreactivity for tau-protein. Only in two healthy cases a single PBL from many cells (i.e. a smear) demonstrated a very weak-positive tau-protein expression (Fig. 1b). Our study demonstrated the localization of tau-protein immunoreactivity only in the cy-

toplasm of PBL (Figs. 1c, d). In some AD cases an extrusion of tau-immunoreactive substance from PBL cytoplasm was observed (Fig. 1e).

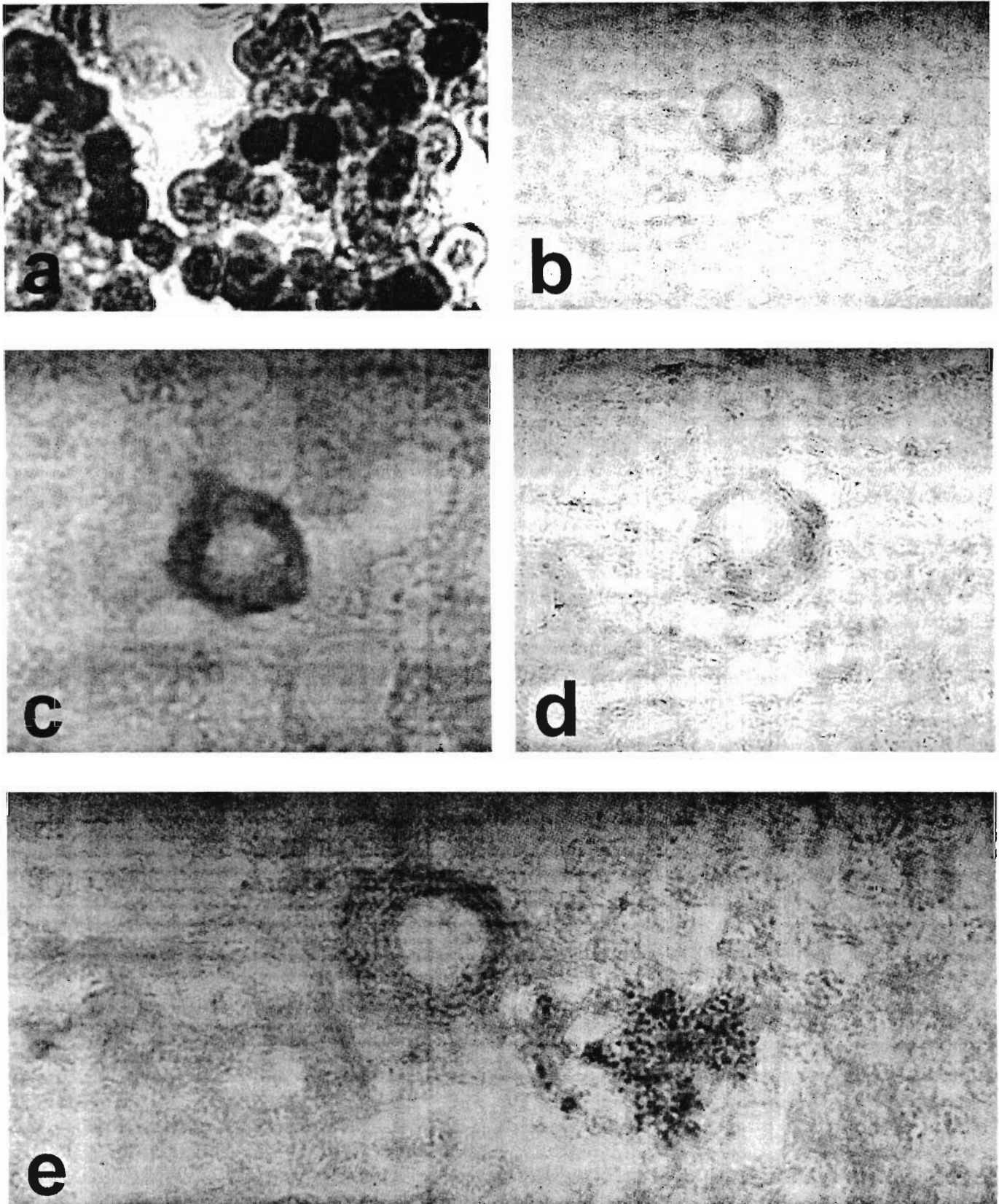
## Discussion

In this paper, using immunocytochemical method, we show for the first time tau-protein expression in PBL cytoplasm in AD patients. In contrast, this molecule was not found in the PBL of healthy volunteers (in fact, very weak immunopositive reaction was observed in only a single lymphocyte of a smear in two healthy cases which could not be considered as a significant feature for discussion). This clear difference in immunolocalization of tau-protein between healthy and sick people strongly supports our idea that this molecule could be a promising marker for life-time diagnosis of AD.

From our point of view, the application of tau-protein for life-time diagnosis of AD is more effective than  $\beta$ -APP because significant amounts of  $\beta$ -APP were not found in human lymphocytes and the clear difference in its localization between healthy and sick people was not obtained. For instance, it was shown, that human peripheral T and B lymphocytes contain small amounts of three major  $\beta$ -APP transcripts ( $\beta$ -APP770,  $\beta$ -APP751,  $\beta$ -APP695) [19], but the microquantitative indices of  $\beta$ -APP in human lymphocytes do not allow using this marker for successful diagnosis of AD and other neurodegenerative diseases.

Taking into account the fact that  $\beta$ -APP is expressed by some non-neural tissues [8, 9], RNA was isolated from the mononuclear blood cells of patients suffering from AD, Down's syndrome, senile dementia non-Alzheimer type and from normal individuals [20]. There was no significant difference in  $\beta$ -APP mRNA levels between any of the groups. This indicates that AD is not accompanied by an increase in production of  $\beta$ -APP in circulating mononuclear blood cells and these results may be considered as serious obstacles for diagnosis to differentiate AD from other disorders with abnormal amyloid metabolism.

Terry proposes to consider AD not only as a result of  $\beta$ -amyloid deposition in the brain but moreover as a pathology of destabilization of the cytoskeleton, in which hyperphosphorylated tau-protein plays a key role [21]. Our data support this point of view because we have obtained the positive immunostain for tau-protein only in PBL cytoplasm and suppose that such localization of tau-protein in lymphocytes reflects its direct connection with microtubules.



**Fig. 1. Tau-protein expression in human PBL.**

a—strong positive reaction of the vast majority of PBL in AD blood smear. x120.

b—very weak-positive tau-protein expression in single PBL. A smear of volunteer without AD. x120.

c,d—tau-protein immunoreactivity is localized only in cytoplasm of PBL. AD (c) and control (d). x600.

e—extrusion of tau-immunoreactive substance from PBL cytoplasm was observed in some AD cases. x900.

a,e—immunocytochemical biotin-streptavidin complex method.

Cells of the hemopoietic lineage (T-lymphocytes, eosinophilic leukocytes, mast cells, etc.) use lysosomes to store and release their secretory products; these organelles have been termed secretory lysosomes [22]. Secretory lysosomes are a mixture of lysosomes and secretory granules [23]. Earlier, it was shown that secretory lysosomes of T-lymphocytes contain soluble proteins required for destruction of virally infected and tumorigenic targets (perforin and granzymes) and also membrane-bound proteins that are essential for controlling the immune response (Fas ligand) [24, 25]. Thus, it could be possible that phosphorylated tau-protein in PBL from AD is produced by their secretory lysosomes also, although this remains to be investigated.

Because some authors [26, 27] noticed the appearance of tau-protein in the olfactory nerve fibers, there were some attempts to use this tissue for early diagnosis of AD. However, Kishikawa and coauthors [28] have analyzed many publications in this field of study and underlined that a positive immunoreaction with anti-tau-protein antibody was obtained in 65.5% of the non-demented subjects even among young volunteers. Hock et al. [29] did not find the presence of tau-protein or  $\beta$ -amyloid in olfactory mucosa from AD patients. These results are consistent with other reports showing that cytoskeletal changes and tau pathology in the olfactory epithelium are not primary (or specific) features of AD and may occur predominantly in late stages of the disease [29]. It follows, that biopsy of the olfactory mucosa cannot be used for early diagnosis of AD.

Thus, our data on the identification of tau-protein in PBL of AD patients and the clear difference in its expression between healthy and sick people allow considering tau-protein as the most promising marker and blood lymphocytes as a suitable extra-brain sample for life-time diagnosis of AD.

### Acknowledgments

Partly, this study has been supported by FIS (Grant 99/0743) and RFBR (Grant 98-04-48763). The temporal work of I.K. as Senior Visiting Researcher at the Instituto de Investigaciones Citologicas (Valencia, Spain) has been supported by the BANCAJA Fellowship.

### REFERENCES

- 1 Simon DK, Johns DR. Mitochondrial disorders: clinical and genetic features. *Annu Rev Med* 1999; **50**:111-127.
- 2 Price DL. New order from neurological disorders. *Nature* 1999; **399** (Suppl): A3-A5.
- 3 Joachim CL, Mori H, Selkoe DJ. Amyloid beta-protein deposition in tissues other than brain in Alzheimer's disease. *Nature* 1989; **341**:226-230.
- 4 Schmitt TL, Steiner E, Klingler P, Lassmann H, Grubeck-Loebenstein B. Thyroid epithelial cells produce large amounts of the Alzheimer beta-amyloid precursor protein (APP) and generate potentially amyloidogenic APP fragments. *J Clin Endocrin Metabol* 1995; **80**:3513-3519.
- 5 Li QX, Evin G, Small D, Multhaup G, Beyreuther K, Masters CL. Proteolytic processing of Alzheimer's disease beta A4 amyloid precursor protein in human platelets. *J Biol Chem* 1995; **270**:14140-14147.
- 6 Gasparini L, Racchi, Binetti G, Trabucchi M, Solerte SB, Alkon D, et al. Peripheral markers in testing pathophysiological hypotheses and diagnosing Alzheimer's disease. *FASEB* 1998; **12**:17-34.
- 7 Miklossy J, Taddei K, Martins R, Escher G, Kraftsik R, Pilleuit O, et al. Alzheimer disease: curly fibers and tangles in organs other than brain. *J Neuropathol Exp Neurol* 1999; **58**:803-814.
- 8 Adler MJ, Coronel C, Shelton E, Seegmiller JE, Dewji NN. Increased gene expression of Alzheimer disease  $\beta$ -amyloid precursor protein in senescent cultured fibroblasts. *Proc Natl Acad Sci USA* 1991; **88**:16-20.
- 9 Gardella JE, Gorgone GA, Munoz PC, Ghiso J, Frangione B, Gorevic PD. Beta protein precursor expression in human platelets and a megakaryocyte cell line. Possible implications for the origin of cerebral amyloidosis in Alzheimer's disease. *Lab Invest* 1992; **67**:303-313.
- 10 Selkoe DJ. The cell biology of  $\beta$ -amyloid precursor protein and presenilin in Alzheimer's disease. *Trends Cell Biol* 1998; **8**:447-453.
- 11 Mandelkow E-M, Mandelkow E. Tau in Alzheimer's disease. *Trends Cell Biol* 1998; **8**:425-427.
- 12 Li QX, Fuller SJ, Beyreuther K, Masters CL. The amyloid precursor protein of Alzheimer disease in human brain and blood. *J Leukoc Biol* 1999; **66**:567-574.
- 13 Spillantini MG, Goedert M. Tau protein pathology in neurodegenerative diseases. *Trends Neurosci* 1998; **21**:428-433.
- 14 Lee VM-Y, Trojanowski Q. Neurodegenerative tauopathies: human disease and transgenic mouse models. *Neuron* 1999; **24**:507-510.
- 15 Tolnay M, Probst A. Review: tau protein pathology in Alzheimer's disease and related disorders. *Neuropathol Appl Neurobiol* 1999; **25**:171-187.
- 16 Thurston VC, Zinkowski RP, Bindler LI. Tau as a nucleolar protein in human nonneural cells in vitro and in vivo. *Chromosoma* 1996; **105**:20-30.
- 17 Feany MB, Dickson DW. Neurodegenerative disorders with extensive tau pathology: a comparative study and review. *Ann Neurol* 1996; **40**:139-148.

- 18 Hyman BT, Trojanowski JQ. Editorial on consensus recommendations for the postmortem diagnosis of Alzheimer disease from the National Institute of Aging and the Reagan Institute working group on diagnostic criteria for the neuropathological assessment of Alzheimer disease. *J Neuropathol Exp Neurol* 1997; **56**:1095–1097.
- 19 Schlossmacher MG, Ostaszewski BL, Hecker LI, Celi A, Haass C, Chin D, et al. Detection of distinct isoform patterns of the beta-amyloid precursor protein in human platelets and lymphocytes. *Neurobiol Aging* 1992; **13**:421–434
- 20 Buckland P, Tidmarsh S, Spurlock G, Kaiser F, Yates M, O'Mahony G, et al. Amyloid precursor protein mRNA levels in the mononuclear blood cells of Alzheimer's and Down's patients. *Brain Res Mol Brain Res* 1993; **18**:316–320.
- 21 Terry RD. The pathogenesis of Alzheimer disease: an alternative to the amyloid hypothesis. *J Neuropathol Exp Neurol* 1996; **55**:1023–1025.
- 22 Griffiths GM. Secretory lysosomes—a special mechanism of regulated secretion in haemopoietic cells. *Trends Cell Biol* 1996; **6**:329–332.
- 23 Stinchcombe JC, Griffiths GM. Regulated secretion from hemopoietic cells. *J Cell Biol* 1999; **147**:1–5.
- 24 Peters PJ. Cytotoxic T lymphocyte granules are secretory lysosomes, containing both perforin and granzymes. *J Exp Med* 1991; **173**:1099–1109.
- 25 Bossi G, Griffiths GM. Degranulation plays an essential part in regulating cell surface expression of Fas ligand in T cells and natural killer cells. *Nature Med* 1999; **5**:90–96.
- 26 Tabaton M, Cammatata S, Mancardi GL, Cordone G, Perry G, Loeb C. Abnormal tau-reactive filaments in olfactory mucosa in biopsy specimens of patients with probable Alzheimer's disease. *Neurology* 1991; **41**:391–394.
- 27 Lee JH, Goedert M, Hill MD, Lee VM-Y, Trojanowski JQ. Tau proteins are abnormally expressed in olfactory epithelium of Alzheimer patients and developmentally regulated in human fetal spinal cord. *Exp Neurol* 1993; **121**:93–105.
- 28 Kishikawa M, Iseki M, Sakae M, Kawaguchi S, Fujii H. Early diagnosis of Alzheimer's? *Nature* 1994; **369**:365–366.
- 29 Hock C, Golombowski S, Muller-Spahn F, Peschel O, Riederer A, Probst A, et al. Histological markers in nasal mucosa of patients with Alzheimer's disease. *Eur Neurol* 1998; **40**:31–36.