



Case Report

Copy Right@ Magen Eli

Immunomodulation with Thymalin in the COVID-19 Related Cytokine Storm: Case Reports

Shapovalov Konstantin G¹, Kuznik Boris I², Lukyanov Sergey A¹, Khavinson Vladimir K^{3,4}, Smolyakov Yuri N¹, Tereshkov Pavel K¹, Shapovalov Yuri K¹, Konnov Valery A¹ and Magen Eli^{5*}

¹Anesthesiology-resuscitation Department, Chita State Medical Academy, Russia

²Normal physiology Department, Chita Medical Academy, Russia

³Saint-Petersburg Institute of Bioregulation and Gerontology, St. Petersburg, Russian Federation, Russia

⁴IP Pavlov Institute of Physiology, St. Petersburg, Russian Federation, Russia

⁵Clinical Immunology and Allergy Division, Medicine C Department, Ben Gurion University of the Negev, Israel

*Corresponding author: Magen Eli, Clinical Immunology and Allergy Division, Medicine C Department, Ben Gurion University of Negev, Zionut 21/33, Ashdod, 77456, Israel.

To Cite This Article: Smolyakov Yuri N, Tereshkov Pavel K, Shapovalov Yuri K, Konnov Valery A, Magen Eli, Immunomodulation with Thymalin in the COVID-19 Related Cytokine Storm: Case Reports. 2020 - 10(6). AJBSR.MS.ID.001574. DOI: [10.34297/AJBSR.2020.10.001574](https://doi.org/10.34297/AJBSR.2020.10.001574).

Received: 📅 October 19, 2020; Published: 📅 November 16, 2020

Abstract

Background: Immunosuppression and “Cytokine storm” in severe coronavirus disease (COVID-19) occur almost simultaneously. The elderly persons with COVID-19 are at high risk for uncontrolled cytokine storm and deep immunosuppression. Thymalin, polypeptide medication obtained from the calf thymus may be used in the treatment of severe COVID-19 patients, using immunomodulatory therapy.

Case presentation: Here we present two patients (the first a 72-year-old male and the second a 69-year-old female) with severe COVID-19 related bilateral pneumonia. In both cases we observed the increased levels of acute-phase reactants and an inflammatory biomarker profile with marked lymphopenia, therefore cytokine storm due to COVID-19 was diagnosed. Both patients were first treated with hydroxychloroquine, cefoperazone/sulbactam, and tocilizumab without any clinical benefit; and was then given thymalin treatment with impressive clinical and laboratory improvement. We performed immunophenotyping of peripheral blood mononuclear cells to assess the dynamics of these cells during COVID-19 related cytokine storm, tocilizumab, and thymalin administration. We observed a decline of CD4+, B-Lymphocytes, and NK-cells after tolicuzimab administration. CD8+ T-cell levels were negatively correlated with inflammatory indicators ESR, CRP, and IL-6.

Conclusions: Thymalin has a beneficial effect on severe COVID-19 related pneumonia and “cytokine storm”. To get more evidence, a randomized, controlled trial of Thymalin in COVID-19 is being performed.

Keywords: Case; Report; Thymalin; Immunomodulation, COVID-19; Cytokine, Storm

Abbreviations: SARS-CoV-2: Severe Acute Respiratory Syndrome Coronavirus 2; COVID-19: Severe Coronavirus Disease 19; HIV: Human Immunodeficiency Virus; ARDS: Acute Respiratory Distress Syndrome; PEEP: Positive End-Expiratory Pressure; PCR: Polymerase Chain Reaction; FiO2: Fraction of Inspired Oxygen; MAS: Macrophage Activation Syndrome; HLH: Hemophagocytic Lymphohistiocytosis; CAR-T: Chimeric Antigen Receptor T Cells; PBMC: Peripheral Blood Mononuclear Cells

Introduction

Infection induced by a novel severe acute respiratory syndrome coronavirus 2 (SARS-CoV-2) coronavirus, named coronavirus diseases 19 (COVID-19), causes acute T cell exhaustion, which might lead to ineffective antiviral immunity [1]. Most COVID-19 cases demonstrated severe lymphocytopenia, especially in aged patients

and severe cases [2]. Age is the strongest predictor of the severity and lethality of COVID-19 [3].

Two important immunological signs of aging are a fall of thymic T cell output and T cell diversity, that leads to a reduced capacity to mount strong adaptive immune responses to new antigens in



later life [4]. Immunosuppression and “Cytokine storm” in severe COVID-19 occur almost simultaneously and have been widely recognized by clinicians, even so, they are not unique to COVID-19 and also occur in other respiratory viral infections [5,6]. The elderly persons are also at high risk for uncontrolled, over-inflammation reactions, and deep immunosuppression [7]. Therefore, it is important to suppress the disproportionate inflammatory response and repair the deep immunosuppression in the treatment of severe COVID-19 patients, using “immunomodulatory therapy”.

Polypeptide medication thymalin obtained from the calf thymus is known to have immunomodulatory properties, enhancing Th1 cytokine production along with T cell differentiation and maturation, augmenting the involvement of a specific T helper cell response in antiviral defense [8]. Thymalin has been successfully used in clinical practice as an adjunct therapy in the treatment of patients infected with influenza, viral hepatitis B and C, herpes simplex and human immunodeficiency virus (HIV); moreover, several clinical studies demonstrated its beneficial effect in the treatment of severe sepsis and acute respiratory distress syndrome (ARDS) [9].

Here we present two patients with severe COVID-19 related bilateral pneumonia and the “Cytokine storm”, who were first treated with hydroxychloroquine, cefoperazone/sulbactam, and tocilizumab without any clinical benefit; and was then given thymalin treatment with impressive clinical and laboratory improvement. Per institutional guidelines, the patients’ consent was obtained before publishing these cases.

Cases Presentation

Case 1

A 72-year-old male patient with body mass index 27.4 kg/m² was admitted to the intensive care unit (ICU) isolation ward of Chita District Hospital (Chita, Russia). He had reportedly tested positive for COVID-19 before arrival at our hospital. On hospital admission, the patient was hypoxic and tachypneic. Arterial blood gas analysis after admission revealed a pH of 7.41, PCO₂ of 32, PO₂ of 44.9, and SaO₂ of 88 %. A chest X-ray revealed bilateral hazy opacities, thus

suggesting possible multifocal pneumonia or pulmonary edema due to ARDS. Transthoracic echocardiography revealed normal values of echocardiographic measurements. The infectious workup, including blood and urine cultures, nasopharyngeal swab PCR testing for influenza (A and B), and respiratory syncytial virus, Legionella urinary antigen were negative. Laboratory results revealed elevated acute phase reactants and lymphopenia and eosinopenia (Table 1). The increased levels of acute-phase reactants, an inflammatory biomarker profile, and profound lymphopenia supported our suspicion of cytokine storm due to COVID-19 [10]. The treatment included mechanical ventilation, hydroxychloroquine, cefoperazone/sulbactam, levofloxacin, and heparin. Additionally, the patient received two doses of tocilizumab (Actemra) at 400 mg administered 12 h apart. On day 6, the patient experienced progressively worsening hypoxemic respiratory failure. He required a 100% fraction of inspired oxygen (FiO₂) and positive end-expiratory pressure (PEEP) of 12 cm H₂O to maintain an oxygen saturation of >90%. He was managed by intermittent prone positioning, fluid restriction, and mechanical ventilation. Laboratory studies revealed a further rising in serum inflammatory markers and a depression of cellular immunity (Table 1).

The first CT scan showed a large area of ground-glass opacity with irregular density in the subpleural regions of both lungs, with ‘crazy-paving sign, predominantly in the lower lobes; on day six, multiple patchy consolidations were apparent in both lungs, with air bronchus-charging sign and thickening of the pulmonary interstitium surrounding the lesions (Figure 1). Because of a lack of tocilizumab efficacy, on day 6 in ICU, the decision was made to discontinue the current medications and to treat the patient with thymalin 10 mg daily intramuscularly injections for 10 days. Within 48 hours of receiving thymalin, the patient showed marked clinical improvement. He had a significant decrease in oxygen requirements and her laboratory inflammatory markers showed a descending trend (Table 1). On day 23 in ICU hospitalization, the patient was weaned to the standard nasal cannula. He was consequently discharged from the hospital without supplemental oxygen when follow-up COVID-19 PCR testing was negative.

Table 1: O₂ requirements, hematological parameters and acute phase reactants during hospitalization in ICU Male, white, 70 years.

	Day 1 Transfer to ICU Tocilizumab + Hydroxichloroquin + Cefoperazone/ sulbactam Levofloxacin	04.07.2020 Start Continue + + +	Day 6 Hydroxichloroquin foperazone/ + Levofloxacin art dosing	10.07.2020 Stop + Ce- sulbactam St Thymalin	Day 17.07.2020 Continuation Thymalin till day 16	13 2020 dosing	Day 23 27.07.2020 Quit ICU
O ₂ (L/min)	5		-		-		3
PEEP, cm H ₂ O	5		16		8		-
FiO ₂ (%)	40%		100%		60%		30%
PaO ₂ , mm Hg	44.9		49.7		147		113

SpO2 (on room air)	86%	88%	95%	93%
WBC (cells x 10 ⁹ /L)	7.24	7.1	11.4	8.53
Neutrophils (cells x 10 ⁹ /L)	5.97	6.67	9.23	5.58
Lymphocytes (cells x 10 ⁹ /L)	0.76	0.56	1.14	1.42
Eosinophils (cells x 10 ⁹ /L)	0.01	0.37	0.3	0.57
Platelets (cells x 10 ⁹ /L)	159	206	246	296
CRP (mg/L)	48.0	92.5	12	15.5
LDH (U/L)	470.9	1240.4	807.8	356
D-dimer (ng/mL)	5000	9500	1250	-
Fibrinogen D (g/L)	11.5	6.8	7.1	6.1
Fibrinogen Clauss (g/L)	3.7	3.6	4.1	3.9
Prothrombin time (s)	12.9	13.8	13.2	12.7
Procalcitonin (ng/mL)	<0.5	0,75	-	-
Neutrophils/Lymphocytes ratio	7.85	11.91	8.09	3.92
Lymphocytes/Monocytes ratio	1.55	2	1.65	1.35
Platelets/ Leukocytes ratio	21.96	29.01	21.57	34.7
iL-6 (pg/ml)	105.3	137	25.5	-
Total T-Lymphocytes (cells/ μ L)	364	375	478	-
CD4+ (cells/ μ L)	222	121	274	-
CD8+ (cells/ μ L)	157	270	231	-
CD4/CD8 ratio	1.41	0,448	1,18	-
CD3+HLA-DR+ (cells/ μ L)	26	77	88	-
Total B-Lymphocytes (cells/ μ L)	129	74	147	-
NK-cells (cells/ μ L)	380	42	302	-
NKT cells (cells/ μ L)	74	33	30	-
WBC-platelet aggregates (cells/ μ L)	3352	3287	5166	-
Lymphocyte-platelet aggregates (cells/ μ L)	132	56	215	-
Monocyte-platelet aggregates (cells/ μ L)	611	270	660	-

Neutrophilic-platelet aggregates (cells/ μ L)	2386	2723	3980	-
T-lymphocyte-platelet aggregates (cells/ μ L)	26	28	55	-

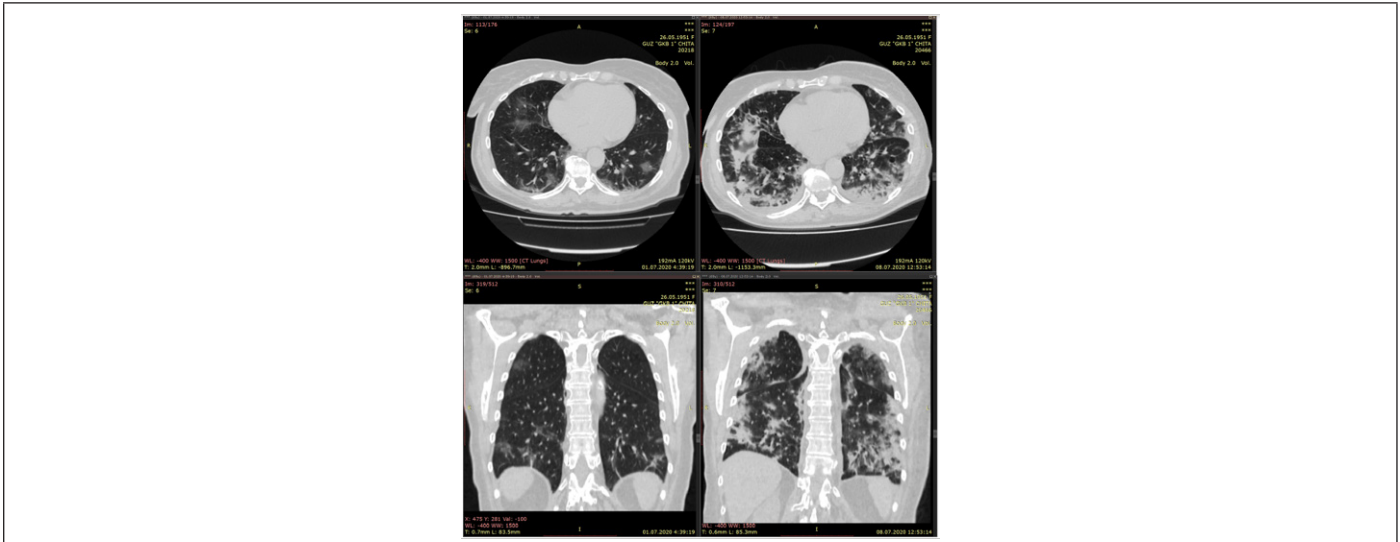


Figure 1: The first CT scan showed a large area of ground-glass opacity with irregular density in the subpleural regions of both lungs, with 'crazy-paving sign, predominantly in the lower lobes; on day six, multiple patchy consolidations were apparent in both lungs, with air bronchus-charging sign and thickening of the pulmonary interstitium surrounding the lesions.

Case 2

A 69-year-old female was admitted to the Chita District Hospital (Chita, Russia) due to worsening respiratory failure and fever. The patient had other comorbid diseases including hypertension for 15 years, coronary heart disease for 5 years, and type two diabetes mellitus for 9 years. The pharyngeal swab RT-PCR test for COVID-2019 was positive. At admission, blood pressure of 145/84 mmHg, and pulse of 94 beats per minute and respiratory rate was 32 per minute. The oxygen saturation values were decreased to as low as 88 % and PaO₂ was 66.2 mmHg. Due to critically severe type COVID-19, the patient was transmitted to the ICU.

As in the previous case, we observed the increased levels of acute-phase reactants and an inflammatory biomarker profile with marked lymphopenia, therefore cytokine storm due to COVID-19 was diagnosed (Table 2). The patient was treated with hydroxychloroquine, intravenous injections of hydroxychloroquine, cefoperazone/sulbactam, levofloxacin, and heparin. The patient also received three doses of tocilizumab (Actemra) at 400 mg. On day 3, the patient was on mechanical ventilation due to hypoxemic respiratory failure, but further worsened lymphopenia, thrombocytopenia, elevated CRP levels, and developed hemodynamic instability, requiring vasopressor support by intravenous noradrenaline.

Table 2: O₂ requirements, hematological parameters and acute phase reactants during hospitalization in ICU Female, white, 69 years.

	Day 1 to ICU + Cefoperazone/	08.07.2020 Start Hydroxichloroquin + subactam Levofloxacin	Transfer Tocilizumab +	Day 3 .2020 Hydroxichloroquin + Cefoperazone/ sulbactam Levofloxacin Start malin	10.07 Stop malin + Thy-dosing	Day 7 17.07.2020 Continuation malin dosing	Con-Thy-malin dosing	Day 23 27.07 .2020 Thy-malin dosing
O ₂ (L/min)		5		5		3		-
FiO ₂ (%)		60		60		40		-
PaO ₂ , mm Hg		6620%		7040%		11000%		-
SpO ₂ (on room air)		88%		92%		94%		95%

WBC (cells x 10 ⁹ /L)	896%	795%	1232%	599%
Neutrophils (cells x 10 ⁹ /L)	6.85	6.62	9.28	3.51
Lymphocytes (cells x 10 ⁹ /L)	0.8	0.66	1.45	1.62
Eosinophils (cells x 10 ⁹ /L)	0.01	0.02	0.03	0.03
Platelets (cells x 10 ⁹ /L)	272	100	409	269
CRP (mg/L)	62.2	96	44.4	6.0
LDH (U/L)	804.7	603.3	378.8	-
D-dimer (ng/mL)	1500	750	-	700
Fibrinogen D (g/L)	10.5	11.1	6.9	6.6
Fibrinogen Clauss (g/L)	3.5	2.0	3.2	3.0
Prothrombin time (s)	12.6	14.2	12.9	12.2
Procalcitonin (ng/mL)	0.5	-	-	-
Neutrophils/ Lymphocytes ratio	8.56	10.03	6.4	2.16
Lymphocytes/ Monocytes ratio	1.02	1.06	1.68	2.1
Platelets/ Leukocytes ratio	30.35	1257	3319	449
iL-6 (pg/ml)	174.8	60.16	-	-
Total T-lymphocytes (cells/ μ L)	400	424	532	-
CD4+ (cells/ μ L)	302	279	359	-
CD8+ (cells/ μ L)	107	153	185	-
CD4/CD8 ratio	2.82	1.82	1.94	-
CD3+HLA-DR+ (cells/ μ L)	46	7	18	-
Total B-lymphocytes (cells/ μ L)	36	82	94	-
NK-cells (cells/ μ L)	90	91	60	-
NKT cells (cells/ μ L)	15	92	68	-
WBC-platelet aggregates (cells/ μ L)	6640	3727	7331	-
Lymphocyte-platelet aggregates (cells/ μ L)	88	66	71	-
Monocyte-platelet aggregates (cells/ μ L)	554	509	1254	-
Neutrophilic-platelet aggregates (cells/ μ L)	5582	2958	6363	-
T-lymphocyte-platelet aggregates (cells/ μ L)	37	22	21	-

Chest CT clearly showed evidence of bilateral pneumonia and ground-glass opacity (Figure 2). Due to high fevers, the patient received antipyretic therapy. We considered the ongoing antibiotic treatment with hydroxychloroquine and tocilizumab to be ineffective, and this drug combination was discontinued. Instead, the patient started thymalin 10 mg daily intramuscularly injections for 10 days. Within 96 hours of receiving thymalin, the patient be-

came hemodynamically stable and showed marked improvement of respiratory failure. Her laboratory inflammatory markers also showed an improving tendency (Table 2). Subsequently, the patient was weaned to the standard nasal cannula and discharged from the hospital without supplemental oxygen and a negative COVID-19 PCR testing.

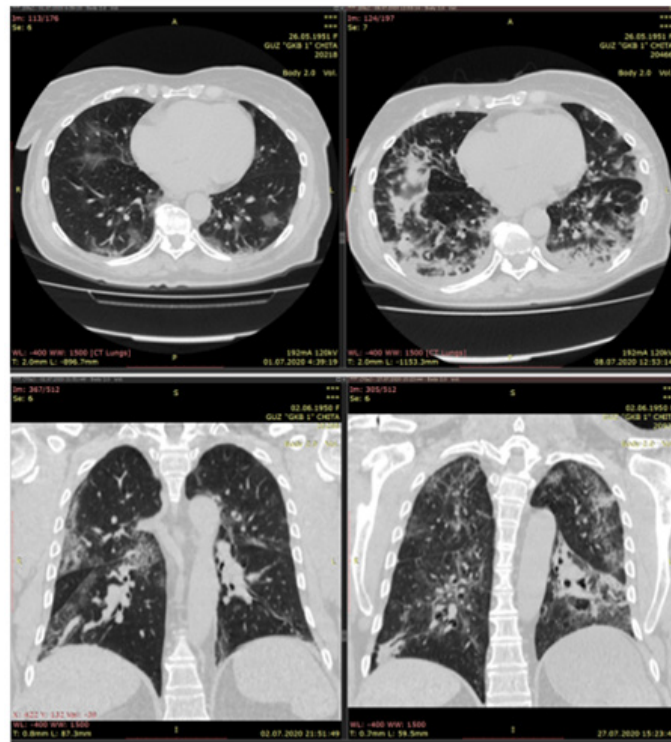


Figure 2: The first chest CT scan clearly showed evidence of bilateral pneumonia and ground-glass opacity; The second CT scan on day 3 shows new multiple consolidations in both lungs, with air bronchus-charging sign and thickening of the pulmonary interstitium surrounding the lesions.

Discussion

In the presented case we observed that thymalin has a beneficial effect on severe COVID-19 related pneumonia and cytokine storm. Impairment of cell-mediated adaptive immunity is very common in COVID-19 patients, and most critically ill cases manifest severe lymphocytopenia [11]. In a recent retrospective study, Liu Y et al. reported that the Thymosin alpha 1 ($T\alpha 1$) supplement significantly reduces the mortality of severe COVID-19 patients [12]. The authors showed that $T\alpha 1$ effectively and quickly augments T cell counts in COVID-19 patients with severe lymphocytopenia, particularly in cases with the counts of CD8+ or CD4+ T cells lower than 400/ μ L or 650/ μ L, respectively [12].

The inflammatory cytokine storm observed in COVID-19 shares features with macrophage activation syndrome (MAS) and hemophagocytic lymphohistiocytosis (HLH) but has some distinguishing characteristics [13]. The clinical features of patients with COVID-19 also parallel those in cytokine release syndrome, which arise as a result of CAR-T cell therapies [14]. The typical clinical picture of a patient with the cytokine storm includes rapid respiratory deterioration [15]. Our patients began to clinically decline and revealed symptoms of progressive respiratory failure on the first day of admission. In both patients the onset of the cytokine storm was evidenced by increased levels of acute-phase markers (D-di-

mer, CRP, LDH, ferritin, IL-6), low platelets, decreased fibrinogen, lymphopenia, coagulopathy, and lung tissue damage. Lymphopenia is a frequently reported feature of COVID-19 induced cytokine storm and lymphopenia with leukocytosis may serve a key feature in the differential diagnosis of severe COVID-19 [16]. As the activation of IL-6 is thought to be the key feature of the progression of COVID-19 pneumonia to ARDS and cytokine storm pathophysiology, IL-6 receptor inhibition has promise as a therapeutic strategy [17]. Accordingly, on day 1 of admission, we started an intravenous administration of tocilizumab 400 mg for the treatment for COVID-19 induced cytokine release syndrome. In our patient, tocilizumab was administered in combination with ongoing hydroxychloroquine and antibiotics on day 1, followed by subsequent doses 12 hours apart. Our patients did not show any clinical improvement after tocilizumab administration, although we administered multiple doses of the drug. In an observational study, Giamarellos-Bourboulis et al. administered tocilizumab to six patients and observed that the absolute lymphocyte levels in the six patients decreased after this therapy [18]. Interestingly, we also observed a decline of CD4+, B-Lymphocytes, and NK-cells after tocilizumab administration. Whether this decline is related to the cytokine storm-related immunosuppression on to tocilizumab treatment, is unknown. The earliest reports of patient outcomes after treatment with tocilizumab for COVID-19 were very small, heterogeneous, and uncontrolled.

Recent observational and randomized studies in hospitalized patients with COVID-19 provide evidence that supports both potential benefit and lack of benefit from tocilizumab treatment [19,20].

In our cases, we performed immunophenotyping of peripheral blood mononuclear cells (PBMC) to assess the dynamics of these cells during COVID-19 related cytokine storm, tocilizumab, and thymalin administration. As CD8+ T-cell levels are negatively correlated with inflammatory indicators ESR, CRP, and IL-6, these cells might be a potential predictor for disease severity and clinical efficacy in COVID-19 infection [21]. Moreover, flow cytometry analysis of PBMC phenotype may help predict the risk of clinical progression of the COVID-19 and more effective adaptive immune responses [22]. WBC-platelet aggregates have been described as an important factor in the pathogenesis of and the adhesion of platelets to leukocytes is a marker of platelet activation and leukocyte function [23]. We measured the amount of WBC-platelet aggregates in the peripheral blood of our patients, including granulocyte, monocyte, and lymphocyte aggregates by a flow cytometric method. Possibly, the observed reinstatement of WBC-platelet aggregates in the peripheral blood after thymalin administration reflects the restoration of WBC function and their activation in the recovery phase.

Lastly, observational and pathological studies in patients with COVID-19 have linked the cytokine storm with a pro-coagulant, thrombotic milieu [24,25]. Previous studies showed a beneficial effect of thymalin on blood coagulation and vasomotor function, especially when it was co-administered with heparin [26]. As COVID-19 infection is associated with coagulopathy from disseminated intravascular coagulation and thrombotic microangiopathy in its early stages; we consider thymalin to be an adjunct to anticoagulant therapy and thromboprophylaxis in patients with COVID-19 pneumonia. Even if our observations show an impressive efficacy of thymalin in COVID-19 related cytokine storm, a major limitation the case reports is a possible bias of open clinical observations.

Conclusion

Thymalin has a beneficial effect on severe COVID-19 related pneumonia and “cytokine storm”. To get more evidence, a randomized, controlled trial of Thymalin in COVID-19 is being performed.

Acknowledgements

Not Applicable

Conflict of Interest

None to declare

References

- Diao B, Wang C, Tan Y, Chen X, Liu Y, et al. (2020) Reduction and Functional Exhaustion of T Cells in Patients with Coronavirus Disease 2019 (COVID-19). *Front Immunol* 11: 827.
- Chen R, Sang L, Jiang M, Yang Z, Jia N, et al. (2020) Medical Treatment Expert Group for COVID-19. Longitudinal hematologic and immunologic variations associated with the progression of COVID-19 patients in China. *J Allergy Clin Immunol* 6749(20) 30638-2.
- Mueller AL, McNamara MS, Sinclair DA (2020) Why does COVID-19 disproportionately affect older people? *Aging (Albany NY)*. 12(10): 9959-9981.
- Fahy GM, Brooke RT, Watson JP, Zinaida Good, Shreyas S Vasanawala, et al. (2019) Reversal of epigenetic aging and immunosenescent trends in humans. *Aging Cell* 18(6): e13028.
- Boomer JS, To K, Chang KC, Osamu Takasu, Dale F Osborne, et al. (2011) Immunosuppression in patients who die of sepsis and multiple organ failure. *JAMA* 306(23): 2594-2605.
- Spencer JV, Religa P, Lehmann MH (2020) Editorial: Cytokine-Mediated Organ Dysfunction and Tissue Damage Induced by Viruses. *Front Immunol* 11: 2.
- Liu Y, Mao B, Liang S, Jia-Wei Yang, Hai-Wen Lu, et al. (2020) Association between age and clinical characteristics and outcomes of COVID-19. *Eur Respir J* 55(5): 2001112.
- Morozov VG, Khavinson VK (1997) Natural and synthetic thymic peptides as therapeutics for immune dysfunction. *Int J Immunopharmacol* 19(9-10): 501-505.
- Saakov BA, Belovolova RA, Bakhutashvili VI (1987) Immunocorrective therapy of the traumatic syndrome. *Biull Eksp Biol Med* 104(7): 73-75.
- Henry BM, de Oliveira MHS, Benoit S, Plebani M, Lippi G (2020) Hematologic, biochemical and immune biomarker abnormalities associated with severe illness and mortality in coronavirus disease 2019 (COVID-19): a meta-analysis. *Clin Chem Lab Med* 58(7): 1021-1028.
- Yang X, Yu Y, Xu J, Huaqing Shu, Jia'an Xia, et al. (2020) Clinical course and outcomes of critically ill patients with SARS-CoV-2 pneumonia in Wuhan, China: a single-centered, retrospective, observational study. *Lancet Respir Med* 8(5): 475-481.
- Liu Y, Pang Y, Hu Z, Ming Wu, Chenhui Wang, et al. (2020) Thymosin alpha 1 (Tα1) reduces the mortality of severe COVID-19 by restoration of lymphocytopenia and reversion of exhausted T cells. *Clin Infect Dis* 630.
- McGonagle D, Sharif K, O'Regan A, Bridgewood C (2020) The Role of Cytokines including Interleukin-6 in COVID-19 induced Pneumonia and Macrophage Activation Syndrome-Like Disease. *Autoimmun Rev* 19(6): 102537.
- Buonaguro FM, Puzanov I, Ascierto PA (2020) Anti-IL6R role in treatment of COVID-19-related ARDS. *J Transl Med* 18(1): 165.
- Quirch M, Lee J, Rehman S (2020) Hazards of the cytokine storm and cytokine-targeted therapy in COVID-19 patients: A Review. *J Med Internet Res* 22(8): e20193.
- Gattinoni L, Coppola S, Cressoni M, Busana M, Rossi S, et al. (2020) COVID-19 Does Not Lead to a “Typical” Acute Respiratory Distress Syndrome. *Am J Respir Crit Care Med* 201(10): 1299-1300.
- Lipworth B, Chan R, Lipworth S, RuiWen Kuo C (2020) Weathering the Cytokine Storm in Susceptible Patients with Severe SARS-CoV-2 Infection. *J Allergy Clin Immunol Pract* 8(6): 1798-1801.
- Giamarellos Bourboulis EJ, Netea MG, Rovina N, Karolina Akinosoglou, Anastasia Antoniadou, et al. (2020) Complex Immune Dysregulation in COVID-19 Patients with Severe Respiratory Failure. *Cell Host Microbe* 27(6): 992-1000.e3.
- Cheng GS, Hill JA (2020) To Toci or Not to Toci for COVID-19: Is That Still the Question? [published online ahead of print, 2020 Jul 31]. *Clin Infect Dis* 1133.
- Somers EC, Eschenauer GA, Troost JP, Jonathan L Golob, Tejal N Gandhi, et al. (2020) Tocilizumab for treatment of mechanically ventilated

- patients with COVID-19 [published online ahead of print, 2020 Jul 11]. *Clin Infect Dis* pp. 954.
21. Wang F, Nie J, Wang H, Qiu Zhao, Yong Xiong, et al. (2020) Characteristics of Peripheral Lymphocyte Subset Alteration in COVID-19 Pneumonia. *J Infect Dis* 221(11): 1762-1769.
 22. Moratto D, Chiarini M, Giustini V, Federico Serana, Paola Magro, et al. (2020) Flow Cytometry Identifies Risk Factors and Dynamic Changes in Patients with COVID-19. *J Clin Immunol* p. 1-4.
 23. Ishikawa T, Shimizu M, Kohara S, Takizawa S, Kitagawa Y, Takagi S. Appearance of WBC-platelet complex in acute ischemic stroke, predominantly in atherothrombotic infarction. *J Atheroscler Thromb* 19(5): 494-501.
 24. Tang N, Li D, Wang X, Ziyong Sun, et al. (2020) Abnormal coagulation parameters are associated with poor prognosis in patients with novel coronavirus pneumonia. *Journal of Thrombosis and Haemostasis* 18(4): 844-847.
 25. Wang T, Chen R, Liu C, Wenhua Liang, Weijie Guan et al. (2020) Attention should be paid to venous thromboembolism prophylaxis in the management of COVID-19. *Lancet Haematol* 7(5): e362-e363.
 26. Khavison VKh, Kuznik BI, Sturov VG, Gladkii PA (2020) Thymalin use for respiratory diseases. Application potential in COVID-19. (1): 1-10.